

**Prospective Analysis of 1000 Patients with Hydroxyapatite-coated Total Knee
Replacements**

Mervyn J Cross, OAM, MD, MBBS, FRACS

Erin N Parish, MHSc

Australian Institute of Musculo-Skeletal Research, Sydney, Australia

Address for Correspondence:

Dr MJ Cross

286 Pacific Highway

Crows Nest Australia 2065

Phone: +61 2 9437 5999

Fax: +61 2 9906 1060

Email: mervcros@ozemail.com.au

Abstract

One thousand consecutive patients that underwent a cementless, hydroxyapatite (HA) coated, stemless, total knee replacement (TKR) over a 9 year period were prospectively studied. Regular postoperative clinical follow up was conducted using the Knee Society score. Mean preoperative score was 96 which improved to 182 and 180 at 5 and 10 years respectively. To date, there have been 7 (0.5%) cases requiring revision, primarily for septic loosening (4 cases) with low rates of other post-operative complications. These results reveal the use of HA in a cementless TKR produces reliable fixation with excellent clinical and functional outcomes that are comparable to the cemented fixation results that are published.

Introduction

Total knee replacement (TKR) is well known as a safe and successful operation for the treatment of advanced knee joint degeneration. Cemented fixation is more frequently used due to its reliable results and as a cheaper alternative to a cementless prosthesis. It has represented the gold standard for TKR due to its proven long-term results and excellent survival rates¹⁻³.

Cementless prostheses were initially designed to provide greater durability, preserve bone stock and remove the need for the use of cement. Design flaws in some early designs,

including failure to maintain tibial cortical contact and the use of titanium femoral components leading to metal osteolysis, resulted in the undermining of the efficacy of such prostheses. Modified cementless designs however have overcome these errors with the medium and long-term results from cementless TKR as good as results found with cemented designs⁴⁻¹⁰.

To improve the quality of fixation with the cementless designs bioceramics such as hydroxyapatite (HA) have been introduced. The effectiveness of HA in augmenting uncemented TKR fixation has been proven¹¹⁻¹⁵. The presence of HA has been shown to encourage bone growth onto the porous coated prostheses. The purpose of this study was to prospectively report on the medium to long-term outcomes of an uncemented, HA coated, TKR in a consecutive series of 1000 patients.

Methods

Between 1992 and 2001, 1000 patients requiring a primary TKR were treated with a cementless HA coated, posterior cruciate ligament retaining, stemless prosthesis implanted by the senior author (MJC) using a standard technique. The Knee Society clinical rating score¹⁶ was used to record the outcome of the surgery (maximum score of 200). Clinical examination was conducted by independent examiners for the duration of the study (either an orthopaedic surgeon completing a fellowship program, orthopaedic registrar or qualified researcher). Following a preoperative score, regular clinical reviews

were carried out at three and six months post operatively and then 1, 2, 5 and 10 years thereafter.

At two years, routine fluoroscopic interface images were taken of the first 200 patients. Screened views of the bone-prosthesis interface were taken under fluoroscopic positioning (Fig. 1). To standardize the protocol, the same two radiographers examined all patients in the same fluoroscopy suite. The position and presence of lucent or sclerotic lines¹⁷ were noted independently by two independent orthopaedic surgeons unconnected with the clinical management of the patients in the study. A line was said to be present if noted by either of the two observers ensuring the false negative rate was as low as possible.

Prosthesis

The prosthesis used was the **Active (DJ Ortho, Sydney, Australia)** uncemented TKR system. The cobalt chrome (CoCrMo) femoral component is designed with the beads recessed into the distal end of the prosthesis. The HA coated femoral component encourages bone ongrowth onto the anterior and posterior surfaces and the chamfer cut surfaces of the femoral component with ingrowth into the distal porous beads. The HA is 70µm thick (crystallinity 75%, porosity 20%), which facilitates osteoblast penetration of the porous beads without blocking the pores.

The titanium alloy (Ti6Al4V) tibial component utilises three methods of fixation. Four press fit lugs, provide rotational stability and initial fixation, the cortical and cancellous bone screws prevent lift off and the HA accelerates bone ingrowth into beads for long-term biological fixation. The lug placement is proportional to the tray size, with an outer diameter of 12.5mm and an inner diameter of 6.5mm. Bone screws are coated with titanium nitride, which reduces potential wear particles from micro-motion. The screw heads are the standard 'AO' 4mm hex head, with sizes ranging from 20-50mm in length. A medical grade ultra high molecular weight polyethylene (UHMWPE) meniscal insert was used in all cases and polyethylene patella component when required.

Results

One thousand patients (Male:Female 479:521) were included in the study with a mean follow up was 6.6 years (2.5-11.3 years). Details of the patients can be seen in Table 1. Osteoarthritis was the primary diagnosis in 94 percent of the patients. Forty-seven patients (4.7%) had previously undertaken a high tibial osteotomy on the operated knee. The majority of the patients (60% of knees) were done either as a simultaneous or staged bilateral procedure with 1429 knees in total for this series. Sixty-four patients have died since the surgery (32 male, 32 female, average age 78 years, average time from surgery; 4.1 years). The average preoperative knee score was 96 and improved to 182 by the five year review with a range of movement of 113 degrees (Table 2).

Post operative complications are reported in Table 3 and Table 4. Revision of the prosthesis was required in 7 cases. Reasons for revision were septic loosening (4), malrotation (1), aseptic loosening (1) and supracondylar fracture (1). Retrieval of prosthesis from a revision for septic loosening was possible in one case and sent for histological examination for osteoinduction into the porous surfaces (Fig 1). There were seventeen knees that developed a deep infection (1.2%). Of these, four required revision of the prosthesis while the remainder were retained by means of open synovectomy (3), arthroscopic synovectomy (6), arthroscopic washout (3) and long-term antibiotics (1). Thromboembolic complications of varying degrees were the most common post operative sequelae affecting 16.6 percent of patients. Cardiac complications, primarily arrhythmias, affected 2.5 percent of the total group.

At the five and ten year reviews, 96 percent (571 of 592 patients) and 87 percent (93 of 107 patients) of patients were successfully followed up in each of the groups respectively. Routine fluoroscopic interface views performed on the initial series of 200 patients revealed minimal evidence of radiolucent lines. There was no evidence of tibial or femoral osteolysis and none with any subsidence of the tibial tray (Fig 2). There has only been one case of clinical loosening requiring revision to date (7.4 years post operatively). This patient also had a TKR performed following a high tibial osteotomy.

Discussion

The results of this series of primary HA-coated, cementless TKR are good in the medium to long-term stage of follow up. Cementless TKR have proven results that are comparable with cemented TKR and have an advantage of preserving bone stock. If initial fixation of HA-coated implants is secure in the early implantation period, then a strong and enduring fixation can be obtained. The use of a HA coating offers a clinically relevant advantage over simple porous coating and provides adequate fixation to prevent mechanical loosening of TKR¹¹⁻¹⁵. The use of a HA coating has the theoretical advantages of osteoconduction, acceleration of bone ingrowth and biological fixation compared to the use of press-fit or porous-coating alone.

To examine accurate bone ingrowth onto the prosthesis this study monitored the initial group of patients via means of fluoroscopic screening. Few studies have examined the interfaces in this way^{8, 18}. Because of the minor malpositioning that invariably occurs during standard radiography, a true anteroposterior (AP) or lateral view of the knee is unlikely to be a true AP or lateral of the prosthesis itself. An apparently true lateral radiograph, for example, when screened into perfect position may then show lucent lines. The results from screening the initial 200 patients was sufficient to not warrant further unnecessary radiation exposure to all patients. Patients are now routinely screened at 10 years to examine bone/prosthetic interface (earlier if patients present symptomatically).

Retrieval of components during a revision procedure for septic loosening made it possible to examine the osseointegration that had occurred. The specimen was obtained from a 74 year old male patient in July 1995 (2.2 years following an initial bilateral primary TKR

procedure in May 1993 for osteoarthritis). Histological examination of the bone/prosthesis interface of the femoral component is shown in Figure 1. Osseointegration of the trabecular bone can be seen surrounding the distal porous coated beaded surface which has also penetrated right through to the edge of the prosthesis (inset).

The rate of infection for this study (1.2 percent) is in keeping with other results that have been published in the literature. Of key interest was the ability to retain the prosthesis within this subgroup. Of the 17 deep infections that occurred, only 4 required revision. Other work has suggested that the ideal method of treatment for a deep infection in an uncemented prosthesis if certain criteria are met is an arthroscopic synovectomy due to the absence of the avascular cement-prosthesis interface¹⁹. While it is not possible to give a definitive conclusion, it is an area that warrants further investigation.

Patient function after surgery in this series has previously been reported with a number of patients able to return to recreational sports and have the ability to kneel on the knee without discomfort^{20, 21}. The range of movement achieved is an above the average range of 100-110 degrees that is commonly presented in the literature. This flexion may account for a greater activity and mobility level in the patients.

This series reveals the use of HA in uncemented TKR produces reliable fixation at a mean 6.6 years post operatively. It is comparable to other methods of fixation as demonstrated with minimal revision and complication rates and incidence of loosening. It

produces excellent clinical results and range of movement with good medical and functional outcomes in the medium to long-term follow-up. A longer term survival analysis is still warranted for conclusive results.

Table 1. Patient details

	Number
Percent female	52.1%
Average Age	68 years (range 34-93)
Unilateral TKR	571
Bilateral TKR	858
- <i>Simultaneous</i>	658
- <i>Staged</i>	200
Total Number of Knees	1429
Average Follow Up	6.6 years (range 2.5-11.3 years)
Diagnosis – OA	94%
Deceased	64

Table 2. Average follow up combined knee scores and range of movement

	Knee Score (Max 200)	Flexion (Degrees)
Pre Operative	96	6-115
3 Month	169	3-107
6 Month	177	2-109
1 year	181	1-113
2 year	183	1-113
5 year	182	1-113
10 year	180	0-115

Table 3. Treatment of patients with deep infection

Treatment	Number of Patients	Average Time from Op (months)
Revision	3	18.0
Open Synovectomy	1	0
Arthroscopic Synovectomy	8	26.4
Arthroscopic Washout	4	40.3
Antibiotics	1	-

Table 4. Post-operative complications

Complication	Number of patients
Cardiac	
- Peri-operative death	2
- Arrhythmia	18
- Myocardial Infarction	5
Thromboembolic	
- Pulmonary Emboli	25
- Asymptomatic DVT	148
- Symptomatic DVT	5
Infection	17
Supracondylar Fracture	5

Table 5. Complications requiring surgery

Complication	Number
Revision	7
Deep Infection	16
Subsequent Patella Replacement	20
Poly Exchange	2
Arthrolysis	7
MUA	16
ORIF (for supracondylar fracture)	2

Figure 1. Histologic view of specimen retrieved at autopsy


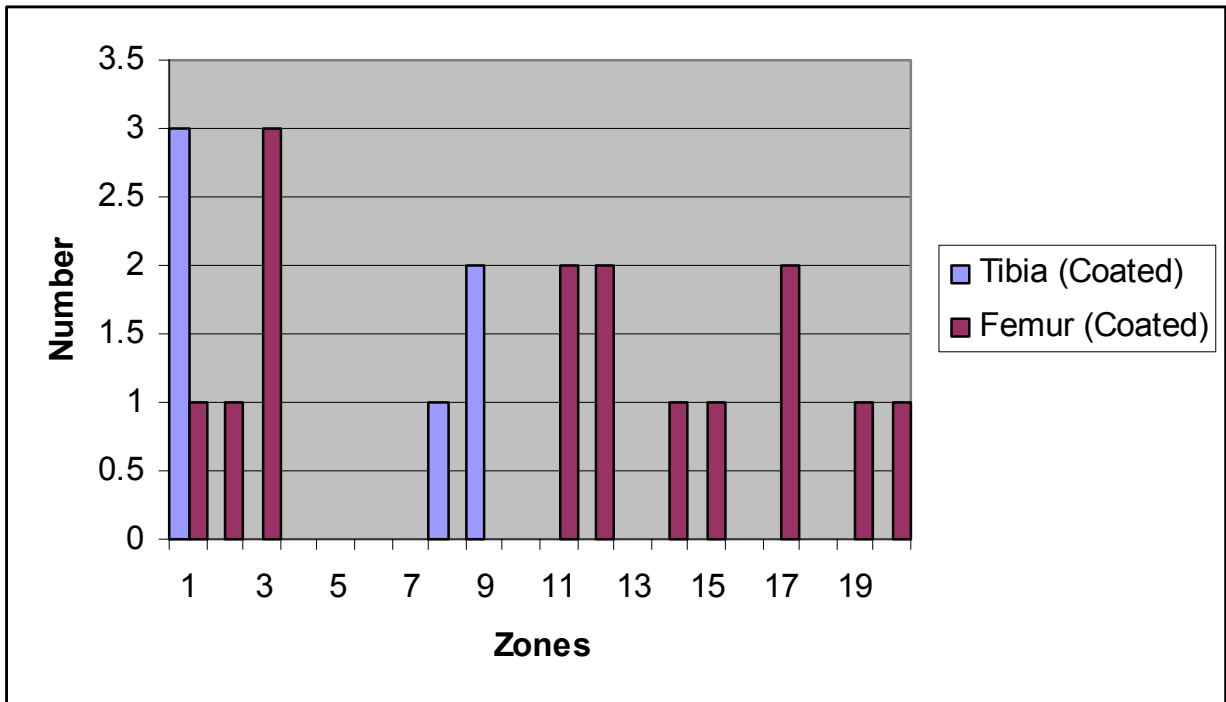


Figure 2. Presence of radiolucent lines in the initial series of 200 patients



References

- 1 Duffy GP, Berry DJ and Rand JA Cement versus cementless fixation in total knee arthroplasty. *Clin Orthop* 1998; 356): 66-72.
- 2 Lachiewicz PF Cement versus cementless total knee replacement: is there a place for cementless fixation in 2001? *Current Opinion in Orthopaedics* 2001; 12(1): 33-36.
- 3 Scuderi GRI, J.N., Windsor, R.E.; Moran, M.C. Survivorship of cemented knee replacements. *J Bone Joint Surg* 1989; 71-B(5): 798-803.
- 4 Hofmann AA, Evanich JD, Ferguson RP, *et al.* Ten- to 14-year clinical follow up of the cementless Natural Knee system. *Clin Orthop* 2001; 388): 85-94.
- 5 Bassett RW Results of 1,000 Performance knees: cementless versus cemented fixation. *J Arthroplasty* 1998; 13(4): 409-13.
- 6 Khaw FK, LMG; Morris, RW; Gregg, PJ A randomised, controlled trial of cemented versus cementless press-fit condylar total knee replacement. *JBJS (Br)* 2002; 84B(5): 658-666.
- 7 Rosenburg AGB, R.; Galante, J.O. A comparison of cemented and cementless fixation with the miller-galante total knee arthroplasty. *Orthop Clin Nth Am* 1989; 20(1): 97-111.
- 8 Nielsen PTH, E.B.; Rechnagel, K. Cementless total knee arthroplasty in unselected cases of osteoarthritis and rheumatoid arthritis. *J Arthroplasty* 1992; 7(2): 137-143.

- 9 Door L Fixation for the millennium - The Knee. *J Bone Joint Surg, Supp II* 2002; 84B(172).
- 10 Schroder HM, Berthelsen A, Hassani G, *et al.* Cementless porous-coated total knee arthroplasty: 10-year results in a consecutive series. *J Arthroplasty* 2001; 16(5): 559-67.
- 11 Gejo RA, S; Takizawa, T Fixation of the NexGen HA-TCP-Coated Cementless, Screwless Total Knee Arthroplasty. *J Arthroplasty* 2002; 17(4): 449-456.
- 12 Toksvig-Larsen SJ, P; Ryd, L et al Hydroxyapatite-enhanced tibial prosthetic fixation. *Clin Orthop* 2000; 370(192-200).
- 13 Nelissen RV, ER; Rozing, PM The effect of hydroxyapatite on the micromotion of total knee prosthesis: A prospective, randomized, double-blind study. *J Bone Joint Surg* 1998; 80-A(11): 1665-1672.
- 14 Onsten IN, A; Carlsson, AS et al Hydroxyapatite augmentation of the porous coating improves fixation of tibial components: A randomised RSA study in 116 patients. *J Bone Joint Surg* 1998; 80-B(3): 417-425.
- 15 Cross MR, G; Holt, M; Bradbury, N; Dixon, P; Parish, EN; Enhanced fixation of uncemented knee replacement with hydroxyapatite. *Key Engineering Materials* 2003; 15(240-242).
- 16 Insall JN, Door, M.D., Scott. R.D., et al Rationale of the knee society clinical rating system. *Clin Orthop* 1989; 248(13-14).
- 17 Ewald FC The knee society total knee arthroplasty roentgenographic evaluation and scoring system. *Clin Orthop* 1989; 248(9-12).

- 18 Mintz ADP, C.A.; Howie, D.W. A comparison of plain and fluoroscopically guided radiographs in the assessment of arthroplasty of the knee. *J Bone Joint Surg* 1989; 71-A(9): 1343-1347.
- 19 Dixon PP, EN; Cross, MJ Arthroscopic Synovectomy - A Viable Option in the Treatment of the Infected Total Knee Replacement. *J Bone Joint Surg* Accepted for Publication, August 2003(
- 20 Palmer SS, CT; Maguire, J; Parish, EN; Cross, MJ Ability to kneel after total knee replacement. *J Bone Joint Surg* 2002; 84-B(220-222).
- 21 Bradbury NB, D; Spoo, G; et al Participation in sports after total knee replacement. *AJSM* 1998; 26(4): 530-535.