

Ganglion Cysts of the Anterior Cruciate Ligament: A Series of 15 Cases

¹EN Parish, MHSc (Ex & Sport Sci)

¹P Dixon, FRCS (Tr & Orth)

¹MJ Cross, OAM, MBBS, MD, FRACS

¹The Australian Institute of Musculo-Skeletal Research

Address of Correspondence:

Dr Mervyn Cross

286 Pacific Highway

Crows Nest, Sydney, Australia

Phone: +61 2 9437 5999

Fax: +61 2 9906 1060

Email: mervcros@ozemail.com.au

Ganglion Cysts of the Anterior Cruciate

Ligament: A Series of 15 Cases

Abstract

Purpose

To evaluate the results of arthroscopic debridement of a series of 15 ganglion cysts related to the cruciate ligaments of the knee.

Type of Study

Case Series

Methods

We present a series of 15 cases recorded over a period of 5 years illustrating the clinical presentation and additional pathology seen at arthroscopy. IKDC scores were calculated at recent follow up to establish outcome of the surgery.

Results

The cysts occurred predominantly in males with the most common presenting complaint being decreased range of movement and pain. Overall, results were excellent with no recurrence of the cysts at mean 36 month follow up but outcome does appear to be associated with other pathology present. Range of movement was improved with arthroscopic excision of the cyst in all cases that were impaired.

Conclusions

Although rare, ganglion cysts related to the cruciate ligaments of the knee should be considered in the differential diagnosis of a painful knee especially when associated with a decreased range of movement and no evidence of osteoarthritis. Other pathology can often be present which may affect the overall outcome but range of movement can reliably be improved with excision of the ganglion.

Keywords: Anterior cruciate ligament, ganglion cyst

Introduction

Ganglion cysts related to the anterior cruciate ligament (ACL) are uncommon. Incidence on MRI in two studies reviewing large numbers of knee examinations was 0.29%¹ and 0.44%². This correlates with a review of 6500 arthroscopic examinations revealing an incidence of 0.54%³. We report a series of symptomatic ACL ganglions treated by arthroscopic debridement.

Methods

Over a 5 year period (July 1997 to September 2002) all arthroscopies performed by the senior author have been prospectively recorded with findings entered into a database. This database was reviewed and the patient presentation, arthroscopic findings and clinical course were examined.

Each patient underwent arthroscopy using a standard 2 portal antero-lateral and antero-medial technique. The ganglion of the ACL was located and debrided using a mechanical shaver taking care not to damage the ACL itself (Figure 1). Other pathology found at the time of arthroscopy was also treated.

Fifteen cases of ganglion cysts (1.10% of all arthroscopies performed throughout this period) related to the anterior cruciate ligament were reported on during this time. The series of 15 cases are presented in Table 1.

Results

The cysts occurred in predominantly males (male: female, 12:3) with a mean age 42 years (range 19-62 years). The most common presenting complaint was pain (13 patients) although this was commonly associated with other symptoms such as decreased range of movement (ROM), instability and stiffness. Eleven patients had an effusion at presentation. Eleven patients had a decreased ROM (average 2-116 degrees) with loss of flexion in 6 cases, extension in 2 cases and both loss of flexion and extension in 3 cases. Six patients had pre-arthroscopy MRI that confirmed the ganglion in 5 cases (Figure 2). Previous arthroscopy had been performed in 4 cases with no evidence of a ganglion of the ACL at that time.

Eleven patients had other pathology within the knee. Nine had chondral damage of varying grades and location within the knee, 1 of these secondary to an inflammatory Arthropathy (patient 2). Five had associated meniscal pathology. Histology was obtained in 7 cases confirming myxoid degeneration in keeping with ganglion formation (Figure 3).

Overall outcome was excellent but appeared to be associated with the presence of other pathology within the joint. Range of movement was improved with arthroscopic excision of the cyst in all the cases that were impaired. All patients were contacted for follow up evaluation at an average of 36 months post surgery (range 9-58 months). An International Knee Documentation Committee⁴ (IKDC) knee score was calculated and the results presented in Table 1. A mean IKDC score of 87 (range 41-99) was obtained with only 2

patients (case 3 and 7) reaching a score of less than 75, both due to the presence of advanced osteoarthritis. There was no recurrence of the cyst in any patient at follow up.

Discussion

The presence of ganglion cysts of the ACL is uncommon with most reports in the literature elucidating only isolated cases⁵⁻¹¹. Common attributes that have been associated with these ganglion cysts are pain, loss of movement (either a block to extension or limited flexion), swelling and effusion. Brown and Dandy³ have presented the most impressive series of operative intervention to date with a report on 38 cases over a 13 year period. The current study presents similar findings with mostly male patients and average age of 40 years most commonly presenting with pain. However, decreased ROM was more common in the current series (73%) indicating the importance of obtaining the main clinical symptom on examination.

The development of magnetic resonance imaging (MRI) and computed tomography (CT) have enhanced the ability to diagnose such abnormalities prior to arthroscopic intervention^{1, 2, 12-14}. Consequently, recent publications have reported on the radiological presentation and non-operative treatment of ganglion cysts of the ACL^{12, 14}. The success of CT has advocated the use of guided aspiration of intra-articular cysts. Reports of such techniques have produced good results, although sample numbers are limited (3 patients¹⁴, 1 patient¹²), but could possibly be considered as an alternative to arthroscopic decompression when associated pathology in the joint is known to be absent.

The reliability of MRI to detect intra-articular ganglions has enabled the incidence of ganglion cysts associated with the cruciate ligaments to be calculated. Two studies have reported an incidence of ganglion cysts of the ACL to be 0.29%¹ and 0.44%² of all MRI examinations performed on the knee. These values are slightly lower than the current study (1.10%) and the study by Brown and Dandy³ (0.54 %) indicating the need for correlation of MRI with clinical symptoms.

Although rare, ganglion cysts related to the cruciate ligaments of the knee should be considered in the differential diagnosis when there is a block to flexion or extension with no evidence of arthritis. Other pathology is often present which may affect the overall outcome but range of movement can reliably be improved with excision of the ganglion.

References

- 1 Huang GS, Lee, C.H., Chan, W.P., Taylor, J.A.M., Hsueh, C.H., Jaun, C.J., Chen, C.Y., Yu, J.S. Ganglion cysts of the cruciate ligaments: MR findings with clinical correlation. *Acta Radiologica* 2002; 43(4): 419-424.
- 2 Do-Dai DD, Youngberg, R.A., Lanchbury, F.D., Pitcher, J.D., Garver, T.H. Intraligamentous ganglion cysts of the anterior cruciate ligament: MR findings with clinical and arthroscopic correlations. *J Computer Assisted Tomography* 1996; 20(1): 80-84.
- 3 Brown MF, Dandy, D.J. Intra-articular ganglia in the knee. *Arthroscopy* 1990; 6(4): 322-323.
- 4 Irrgang JJ, Anderson AF, Boland AL, *et al.* Development and validation of the international knee documentation committee subjective knee form. *Am J Sports Med* 2001; 29(5): 600-613.
- 5 Johnson WL, Corzatt, R.D. Ganglion cysts of the anterior cruciate ligament. *Am J Sports Med* 1993; 21(6): 893-894.
- 6 Liu SH, Osti, L., Mirzayan, R. Ganglion cysts of the anterior cruciate ligament: A case report and review of literature. *Arthroscopy* 1994; 10(1): 110-112.
- 7 Noda M, Kurosaka, M., Maeno, K., Mizuno, K. Ganglion cysts of the bilateral cruciate ligaments. *Arthroscopy* 1999; 15(8): 867-870.
- 8 Roeser WM, Tsai, E. Ganglion cysts of the anterior cruciate ligament. *Arthroscopy* 1994; 10(5): 574-575.
- 9 Wang CJ. Multiple ganglion cysts of the knee. *Arthroscopy* 2002; 18(8): E42.
- 10 Deutsch A, Veltri, D.M., Altchek, D.W., Potter, H.G., Warren, R.F., Wickiewicz, T.L. Symptomatic intra-articular ganglia of the cruciate ligaments of the knee. *Arthroscopy* 1994; 10(2): 219-223.
- 11 Yasuda K, Majima, T. Intra-articular ganglion blocking extension of the knee: Brief Report. *J Bone Joint Surg* 1988; 70-B(5): 837.
- 12 Campagnolo DI, Davis, B.A., Blacksin, M.F. Computed tomography - Guided aspiration of a ganglion cyst of the anterior cruciate ligament: A case report. *Arch Phys Med Rehab* 1996; 77(7): 732-733.
- 13 Sumen Y, Ochi, M., Deie, M., Adachi, N., Ikuta, Y. Ganglion cysts of the cruciate ligaments detected by MRI. *International Orthopaedics* 1999; 23(1): 58-60.
- 14 Antonacci VP, Foster, T., Fenlon, H., Harper, K., Eustace, S. Technical report: CT-guided aspiration of anterior cruciate ligament ganglion cysts. *Clinical Radiology* 1998; 53(10): 771-773.

Table 1: Patient descriptive data

Case	Gender	Age (years)	ROM	Presenting Complaint	Effusion	Associated Pathology	Histology	MRI	Previous Surgery	Time From Op (Months)	IKDC ³	Recurrence of Cyst
1	M	25	Full	Pain	No	Meniscal	No	Negative	No	51	97	No
2	M	44	Full	Pain	Yes	Chondral (PA ¹)	No	N/A ²	Yes	34	92	No
3	M	71	5-120	Pain	Yes	Meniscal and chondral	No	N/A	Yes	27	41	No
4	M	30	0-110	Pain	No	None	Yes	Positive	No	58	79	No
5	M	34	10-130	Locking	Yes	None	Yes	N/A	No	52	95	No
6	F	47	0-100	Stiffness	No	None	No	Positive	No	50	92	No
7	M	62	5-130	Pain	Yes	Chondral	Yes	N/A	No	41	64	No
8	M	28	0-110	Pain	Yes	Meniscal and chondral	No	N/A	Yes	41	98	No
9	M	52	Full	Pain	Yes	Chondral	Yes	N/A	No	40	98	No
10	M	55	5-110	Pain	Yes	Meniscal and chondral	No	N/A	No	38	98	No
11	M	29	Full	Pain	Yes	Chondral	No	N/A	No	38	99	No
12	F	49	0-80	Pain	Yes	None	Yes	Positive	No	25	79	No
13	F	46	5-120	Pain	Yes	Chondral	Yes	N/A	Yes	24	84	No
14	M	19	0-120	Pain	Yes	Chondral	Yes	Positive	No	9	94	No
15	M	43	0-90	Pain	Yes	Meniscal	No	Positive	No	11	94	No

¹ Psoriatic Arthropathy

² Not Available

³ International Knee Documentation Committee

Figure Legends

Figure 1. Arthroscopic view of ganglion cyst of the anterior cruciate ligament

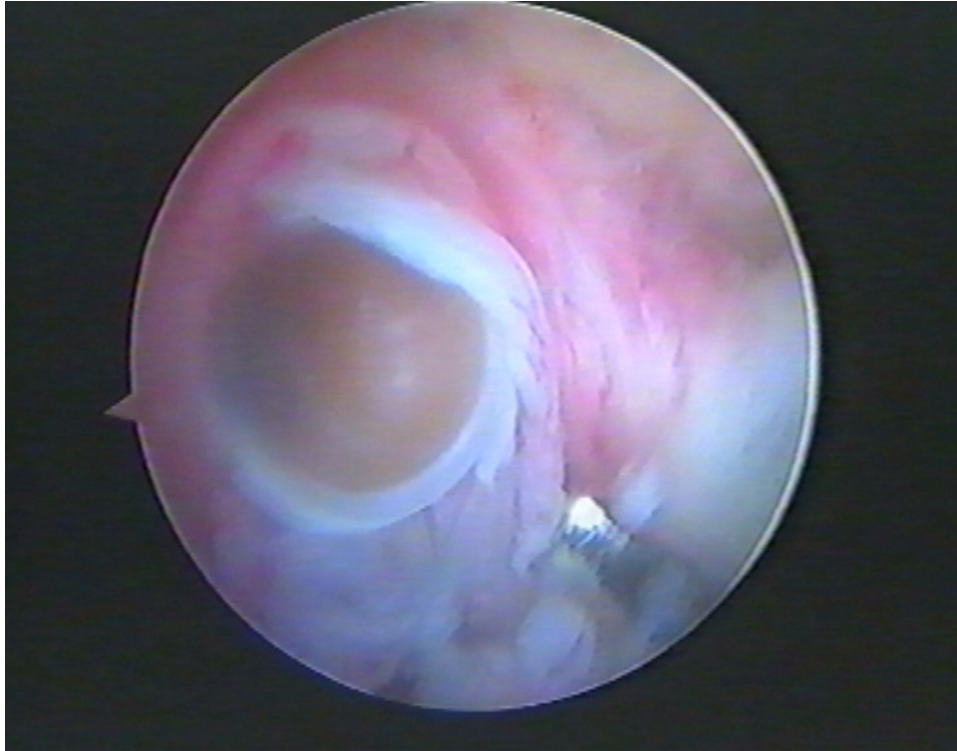


Figure 2. (A) A sagittal proton density image with fat saturation (TR/TE 3500/31.3) showing a posterior ganglion cyst of the ACL causing loss of flexion and is easily missed at arthroscopy, and (B), a coronal proton density image (TR/TE 3200/34.6) showing the same cyst causing impingement in the femoral notch.

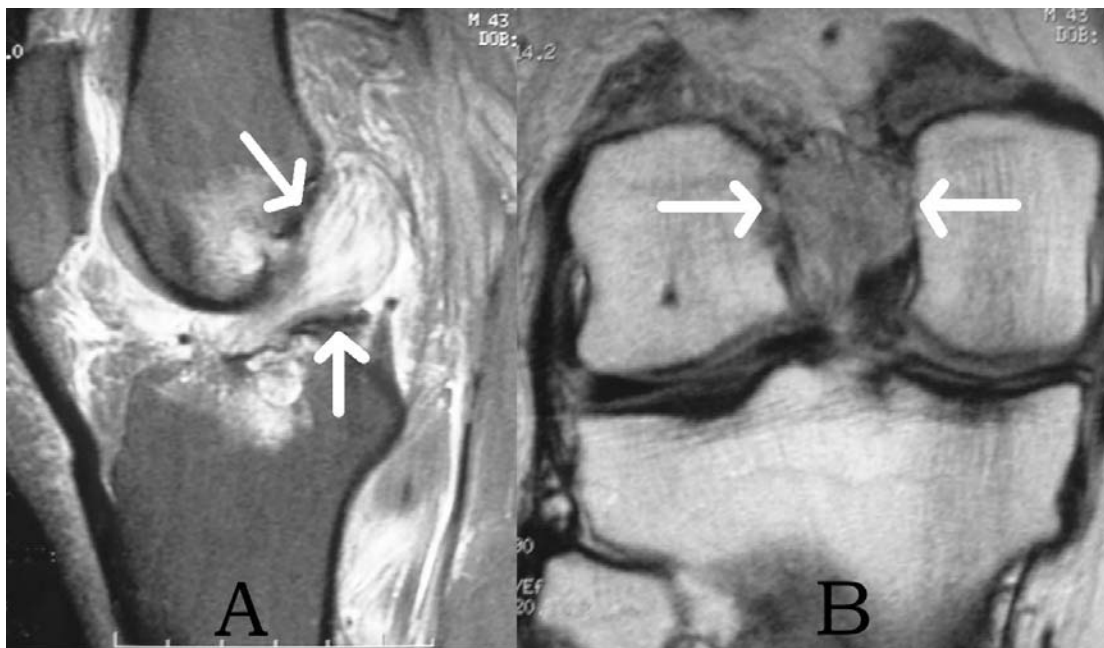


Figure 3. Histology section of ganglion cyst wall taken from the anterior cruciate ligament demonstrating mucoid degeneration (H&E, magnification x200)

