

A New Technique for the Assessment of Intra-operative Femoral Component Rotation in Total Knee Arthroplasty: The Anterior Femoral Cortical Line

S H Palmer, C T J Servant, J Maguire E N Parish M J Cross

Introduction

Accurate rotation of the femoral component in total knee arthroplasty is important for normal patella tracking, symmetrical patellofemoral joint contact, neutral varus-valgus positioning in flexion, correct rotational alignment of the tibia in extension and the avoidance of anterior femoral notching^{1,2}. Internal rotation of the femoral component causes a shift into valgus alignment with flexion and also an increase in the “quadriceps” (Q) angle with deleterious effects on patella tracking. Internal rotation of the femoral component also causes differences in the flexion and extension gaps by altering the relative dimensions of the posterior condyles in flexion. Flexion then causes asymmetrical tension across the prosthesis and gapping on the lateral side¹.

Rotational alignment of the femoral component at the time of surgery has traditionally been assessed using one of three anatomical landmarks for reference: the anteroposterior (AP) axis (or Whiteside’s line), the epicondylar axis and the posterior condylar axis.

The AP axis is a line drawn from the deepest part of the trochlear groove anteriorly to the centre of the intercondylar notch posteriorly². It has been shown to be accurate in determining femoral rotation^{2,3} and places the component 4.4 – 5.5 degrees externally rotated relative to the epicondylar axis³. Criticisms of this line include difficulty in its identification in trochlear dysplasia or destructive arthritis⁴ and excessive rotation in knees with significant varus or valgus deformity⁵.

The epicondylar axis is accurate as a landmark for neutral rotation^{4, 6-8,9,10} and is considered easier to locate intra-operatively than the AP axis and posterior condylar axis, particularly in revision cases. Some authors consider the epicondylar axis difficult to define³ because the epicondylar peaks are often obscured by the everted patella, overlying collateral ligaments and adipose tissue. Use of the surgical epicondylar axis rather than the clinical epicondylar axis has been suggested as a way of improving identification of these landmarks⁶.

The posterior condylar axis is used widely but is inaccurate at defining neutral rotation in a significant number of patients^{4,6-9,11,12}. This axis is particularly imprecise in knees with significant arthritic changes or in knees with a valgus deformity². Use of the posterior condylar axis is a common cause of femoral component internal rotation and should only be used with reference to other anatomical landmarks.

The purpose of this study was to investigate a new linear landmark that can be used in the assessment of femoral component rotation. The “anterior femoral cortical line” (AFCL) is described and compared with the AP axis in both a clinical and a cadaveric study.

Methods

Cadaveric Study

50 normal cadaveric femora were obtained from a local university medical facility. The two points indicating the AP axis (as described above) were identified and marked on each femur with pins.

The anterior femoral cortical line (AFCL) is a line along the flattest part of the anterior cortex of the distal femur, perpendicular to the long axis of the femur. This area may be identified by palpating the anterior cortex of the distal femur proximal to the trochlea; a plateau or slight depression should be felt at the transition between the concavity formed by the anterior femoral (supracondylar) ridges distally and the convexity of the femoral shaft proximally (see Figures 1 and 2). Once located, the AFCL was marked with a straight rigid wire secured on the surface of the anterior femoral cortex.

A true end-on digital photograph of the distal femur resting on a hard surface was taken. A two-dimensional image of each photograph was created by printing each image onto plain paper (see figure 3). The AP axis was drawn between the two marker pins on each photograph. A perpendicular was drawn to the AP axis and the angle between this line and the AFCL was measured. The direction of rotational malalignment (internal or external) was also recorded. The mean difference between the AFCL and the AP axis (together with the range and standard deviation) was calculated.

Clinical Study

58 consecutive patients undergoing total knee arthroplasty for osteoarthritis of the knee were included in the clinical study. After a routine exposure the AP axis was marked on each distal femur with fine-tipped electrocautery. The AFCL was palpated as described above. The flat surface of a cutting block or a straight rigid wire was used across the line as a guide. Using an appropriately sized AP cutting block, chosen to avoid anterior notching, the anterior femoral cortical cut was made parallel to this line.

The angle between this cortical cut and the AP axis was measured using a sterile goniometer from a direct “end on” position. The mean difference between the AFCL and the AP axis (together with the range and standard deviation) was calculated. After implantation of the total knee arthroplasty components, patella tracking was assessed using a ‘no thumb’ technique. Any patellar maltracking was corrected by performing a lateral retinacular release, which was recorded in the study results.

Results

8 knees in the clinical study had destruction of the trochlea that prevented accurate identification of the AP axis. These knees were excluded from the study, leaving 50 knees with valid results. The results from both the cadaveric study and the clinical study are shown in table 1. The lateral release rate for the 50 knees included in the clinical study was 4%.

Table 1: The angular difference between the AFCL and AP axis (degrees).

	Cadaveric Study	Clinical Study
Mean difference between AFCL and AP axis	-7.02	-4.1
Range	-22 to +4	-15 to +4
Standard Deviation	5.1	3.8

* - = internal rotation, + = external rotation

Discussion

The neutral rotational axis of the distal femur is a difficult concept to define. Distal femoral morphology varies widely and so there can be considerable range of angular measurements for all the axes described for the assessment of femoral rotation^{2-9,11,12}. It is therefore prudent to use more than one axis to ensure that the extreme values sometimes encountered do not result in significant malrotation.

Each axis has its own problems. The AFCL does not have the restricted access or lack of definition of the epicondylar axis since the anterior femur is usually clearly exposed in the anterior approach used for total knee arthroplasty. The AFCL is also not affected by trochlea dysplasia and degeneration and may be a useful rotational guide in this situation. The AFCL is also useful in the revision situation where many of the other distal femoral landmarks are absent.

Is the AFCL an accurate guide to femoral rotation? Both the clinical and the cadaveric results show that the AFCL is usually internally rotated when compared to the AP axis. However it is important to bear in mind that, on average, the AP axis is approximately 5 degrees externally rotated to the epicondylar axis³. This means that, in the cadaveric study, the AFCL was a mean of about 2 degrees internally rotated to the epicondylar axis, and, in the clinical study, the AFCL was a mean of about 1 degree externally rotated to the epicondylar axis. This implies that the AFCL is an acceptable indicator of neutral rotation.

There are some potential pitfalls in using the AFCL that need to be mentioned. In a normal distal femur the lateral ridge on the anterior surface is more prominent than the medial and often extends more proximally. It is very important to palpate the AFCL proximal to this ridge to avoid internal rotation of the femoral component (figure 4). It is also important not to palpate the femur too proximally. The anterior cortex of the femoral shaft is convex and thus is wholly unreliable as an anatomical landmark (figure 4).

A useful check of correct rotational alignment, once the anterior cortical cut has been completed, is the “Steinway sign”. This describes the appearance of the cut anterior surface of the distal femur as viewed from above (figure 5). It is produced by more of the lateral femoral ridge being removed than the medial because of their difference in size (figure 6).

Conclusions

The anterior femoral cortical line is a useful guide to femoral component rotation in total knee arthroplasty. It has the advantages of easy access and because of its extra-articular position is not affected by dysplasia or processes that destroy the joint (such as degeneration or osteolysis). It is important to be accurate when defining this axis at surgery and initially it should be used with other more familiar rotational landmarks. Once accustomed to the morphology of the anterior distal femur the AFCL can be used as the primary axis for judging femoral component rotation.

References

1. Anouchi YS, Whiteside L, Kaiser A and Milliano M. The effects of axial rotation alignment of the femoral component on knee stability and patella tracking in total knee arthroplasty demonstrated on autopsy specimens. *Clin Orthop* 1993; 287: 170-177.
2. Whiteside L, Arima J. The anteroposterior axis for femoral rotational alignment in valgus total knee arthroplasty. *Clin Orthop* 1995; 321: 168-172.
3. Arima J, Whiteside L, McCarthy D, White S. Femoral rotational alignment based on the anterior-posterior axis in total knee arthroplasty in a valgus knee: a technical note. *J Bone Joint Surg* 1995; 77-A : Pages 1331–1334.
4. Griffin FM, Math K, Scuderi GR, Insall JN & Poilvache PL. Rotational landmarks and sizing of the distal femur in total knee arthroplasty. *J Arthroplasty* 2000 Apr; 15(3): 354-359
5. Nagamine R, Miura H, Inoue Y, Urabe K, Matsuda S, Okamoto Y, Nishizawa M & Iwamoto Y. Reliability of the anteroposterior axis and the posterior condylar axis for determining rotational alignment of the femoral component in total knee arthroplasty. *J Orthop Sci* 1998; 3(4): 194-198
6. Berger RA, Rubash HE, Seel MJ, Thompson TH and Crossett LS Determining the rotational alignment of the femoral component in total knee arthroplasty using the epicondylar axis. *Clin Orthop* 1993; 286: 40-47.
7. Yoshioka Y, Siu D and Cooke TDV. The anatomy and functional axis of the femur. *J Bone Joint Surg.* 1987; 69-A: 873-880.
8. Olcott CW & Scott RD A comparison of 4 intraoperative methods to determine femoral component rotation during total knee arthroplasty. *J Arthroplasty* 2000 Jan; 15(1): 22-26
9. Mantas JP, Bloebaum RD, Skedros JG & Hofmann AA. Implications of reference axes used for rotational alignment of the femoral component in primary and revision knee arthroplasty. *J Arthroplasty*; 1992 (4): 531-535.
10. Stiehl JB & Abbot BD. Morphology of the transepicondylar axis and its application in primary and revision total knee arthroplasty. *J Arthroplasty* 1995 Dec; 10(6): 785-789
11. Griffin FM, Insall JN & Scuderi GR. The posterior condylar angle in osteoarthritic knees. *J Arthroplasty* 1998 Oct; 13(7): 812-815

12. Matsuda S, Matsuda H, Miyagi T, Sasaki K, Iwamoto Y & Miura H. Femoral condyle geometry in the normal and varus knee *Clin Orthop* 1998; (349): 183-189.

Figure 1. Anterior view of the distal femur demonstrating: (I) the anterior ridges, (II) the anterior femoral cortical line, and (III) the anterior surface of the shaft of the femur.

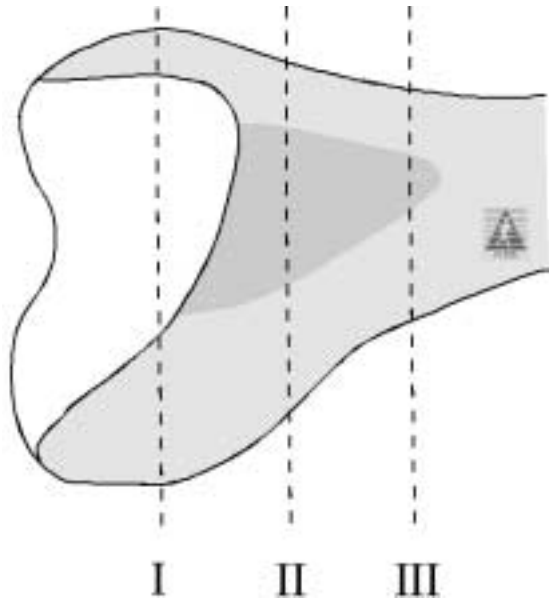


Figure 2. Sagittal view of the same region demonstrated in Figure 1.

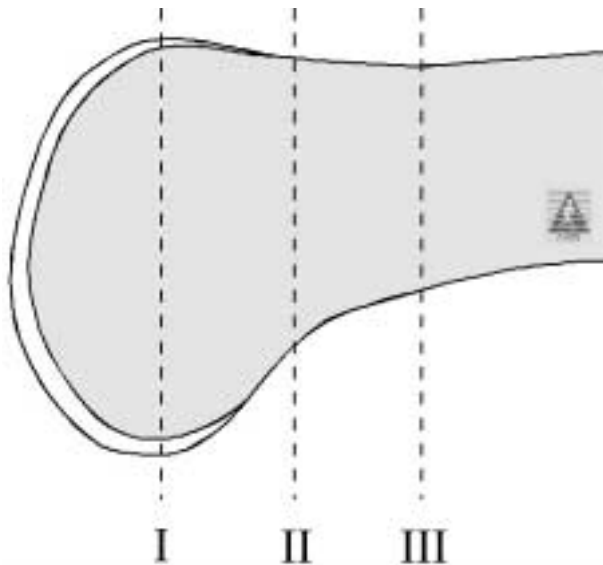


Figure 3. An example of a distal femur showing the AFCL and Whiteside's Line.

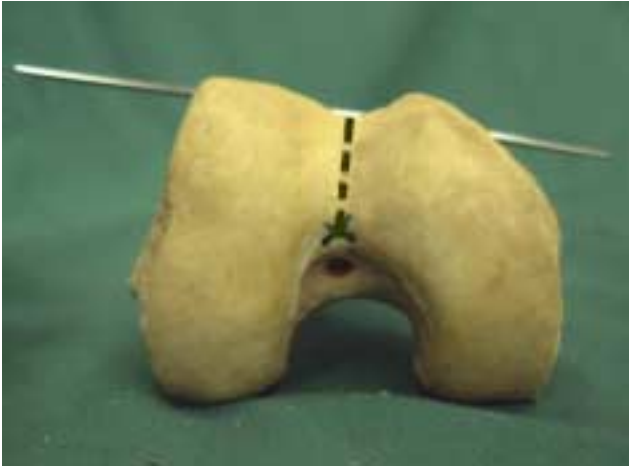

Figure 4. Cross Sections of the distal femur show the 3 regions described in Figures 1 and 2. (II) demonstrates the correct placement of the AFCL.

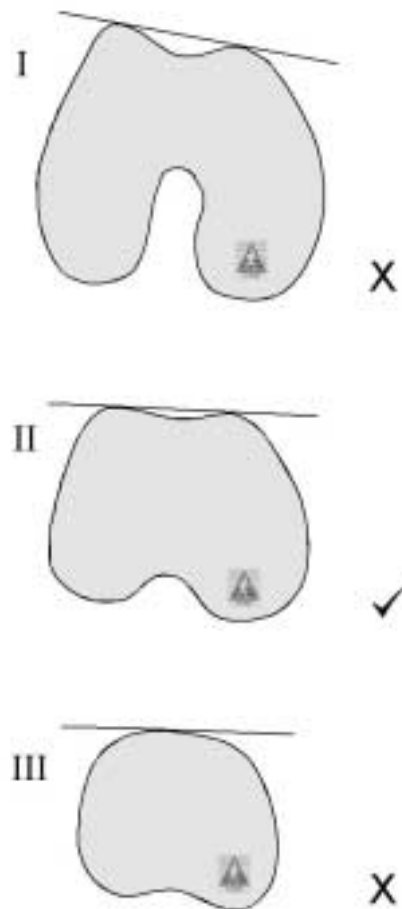


Figure 5. The “Steinway Sign”.

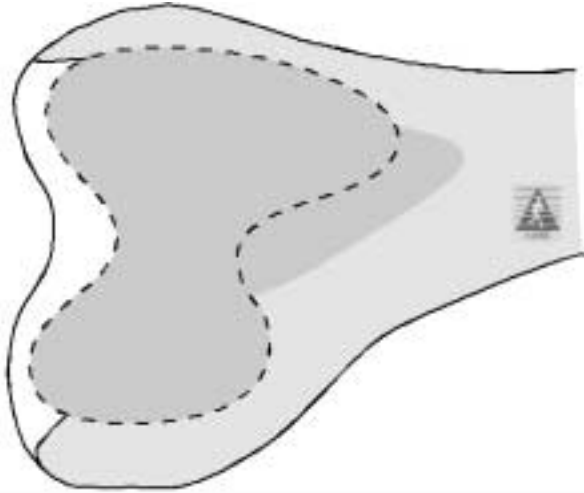


Figure 6. Demonstration of the anterior cortical cut referenced from the AFCL.

