

SURGICAL REPAIR OF CHRONIC COMPLETE HAMSTRING RUPTURE IN THE ADULT PATIENT

M Cross, R Vandersluis, D Wood, M Banff

The American Journal of Sports Medicine, Vol. 26, No. 6: 785-788, 1998

Complete rupture of the hamstring tendons in the adult is a rare injury. This report discusses complete rupture of the hamstring muscles in nine patients treated by late operative repair. All patients were referred from outside centres for a second opinion after failed non-operative treatment. The diagnosis was made quite easily on clinical grounds and confirmed at surgery. Surgical treatment in all cases consisted of reattachment of the hamstring origin to the ischium and in all cases it was necessary to perform neurolysis of the sciatic nerve. Good results were achieved in all cases; at follow up all patients were satisfied with the surgery.

INTRODUCTION

Acute ruptures of the hamstring muscles are a rare clinical entity. It is difficult to diagnosis acutely as there is minimal clinical awareness, which is quite ironic, as the torn hamstring is one of the most common muscle injuries in sport. The massive swelling that occurs with complete ruptures masks makes it difficult for the examiner to detect the defect in the muscle tendon unit. Previous reports in the literature in the adult are scarce². Complete avulsion with gross displacement of the ischial tuberosity is also rare in the teenager and has been recorded with good results with late repair³. The purpose of this study was to determine that late repair of complete tendon ruptures is possible and can give functional results.

METHOD

A retrospective review of the clinical records at the North Sydney Orthopaedic and Sports Medicine Centre over the last 15 years demonstrated nine patients (eight men and one women) with complete rupture of the hamstring tendons (Table 1). The age of patients at time of injury ranged from 21 to 54 years (average, 34). Eight of the nine patients had been recreation and sports enthusiasts before their injury. Eight injuries occurred during sports and one resulted from an awkward fall. Falling while water skiing was the cause of injury in five cases. All of these patients had experienced the same mechanism of being pulled out of the water with the knee at full extension and acute flexion of the hip.

Table 1. Data on the nine patients with hamstring rupture in this study

<i>Patient</i>	<i>Sex</i>	<i>Age (years)</i>	<i>Side of injury</i>	<i>Cause of injury</i>	<i>Symptoms</i>	<i>MRI</i>	<i>Time to repair (months)</i>	<i>Sport</i>			<i>Follow Up (months)</i>
								<i>Pre-injury</i>	<i>Pre Op</i>	<i>Post Op</i>	
1	M	21	R	Rugby	Difficulty running, weakness	+	26	Rugby	None	Rugby	52
2	F	54	L	Fall	Difficulty walking, parathesia		37	None	None	None	31
3	M	29	R	Basketball	Difficulty running		104	Basketball	None	Basketball	37
4	M	31	R	Water skiing	Difficulty running, walking down hill	+	8	Running	None	Running	38
5	M	26	L	Water skiing	Difficulty running, weakness	+	36	Basketball	Basketball	Basketball	12
6	M	47	L	Water skiing	Difficulty running, weakness	+	2	Tennis	None	Tennis	16
7	M	26	L	Rugby	Difficulty running, weakness		75	Rugby	Rugby	Rugby	156
8	M	36	R	Water skiing	Difficulty running, parathesia		23	Jogging	None	Jogging	12
9	M	35	L	Water skiing	Difficulty running	+	2	Water skiing	None	Water Skiing	6

Leg weakness was stated as the main reason for seeking medical attention, with two patients complaining of difficulty with leg control while walking downhill and sic complaining of difficulty with running. Two of the patients complained of significant sciatica as well. When first seen at our medical centre, each patient had a posterior midhigh mass and palpable gap. These symptoms were accentuated by having the patient perform a hamstring muscle contraction in the prone position (Fig. 1). Clinical examination revealed gross weakness of knee flexion and in all cases a palpable gap accentuated with muscle contraction and accompanied by a muscle bulge was seen. Radiographs demonstrated no bony lesion from the ischium in any of the patients. Magnetic resonance imaging (MRI) has been employed in the last five cases but was unavailable in the earlier cases (Fig. 2). This imaging method helps to define the rupture anatomically.

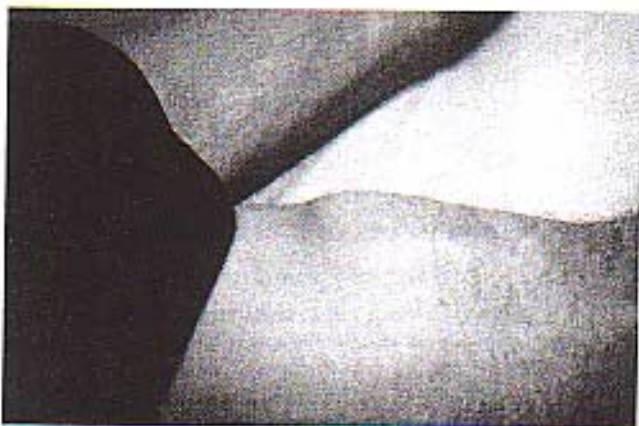

Figure 1. A preoperative clinical photograph of the patient in the prone position shows a palpable mid-posterior-thigh mass and proximal hamstring defect

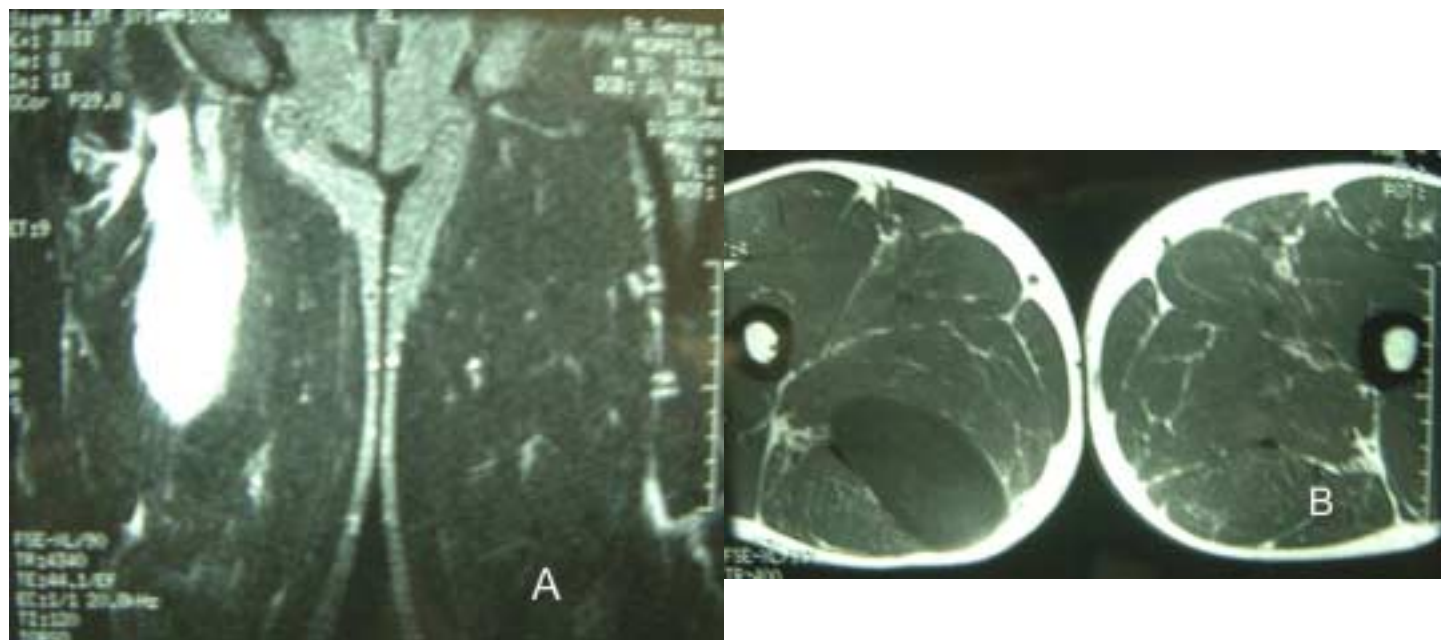


Figure 2. Coronal T2-weighted (A) and axial T1-weighted (B) MRI sections

The patients had been told previously by their treating physicians that it was too late to repair the tendons as they would be contracted and impossible to repair, but some of the patients had been incapacitated enough to seek a second opinion. This study reviews nine patients who had had delayed repair of complete ruptures and who were brought back to our centre to assess their results. The time from injury to repairs varied from 2-104 months with an average of 36 months. Follow-up ranged from 6-156 months, with an average of 46 months. This study was a clinical review of the results of surgery. The Ethics Committee of the Australian Institute of Musculo-Skeletal Research accepted the study as a clinical review.

Surgical exploration was undertaken with the patients in the prone position. A longitudinal incision was made over the defect. In all cases there was massive scar tissue surrounding the sciatic nerve making it necessary to perform a careful neurolysis to isolate this important structure. The nerve was approached below the area of rupture in the area of normal anatomy and dissected proximally. In three cases the distal tendon rupture was encased in a large fluid filled sack, which was seen quite easily on the MRI scan.

After isolating the nerve, the ruptured tendons were defined from the scar tissue and tagged with No. 5 Ethibond sutures (Ethicon Inc. Somerville, New Jersey). The proximal tissue was then defined on the ischium and in only two cases were distinct tendons isolated; however, there was scar tissue present in the other cases. It was possible to implant deep sutures into this tissue but in some cases we needed to use Stay-Tec sutures (Zimmer, Inc., Warsaw, Indiana) into the bone (Fig. 3). These sutures were then passed through the proximal end of the distal tendon. In every case we had to flex the knee to 90° in order to oppose the ruptured tendon ends to the ischium.

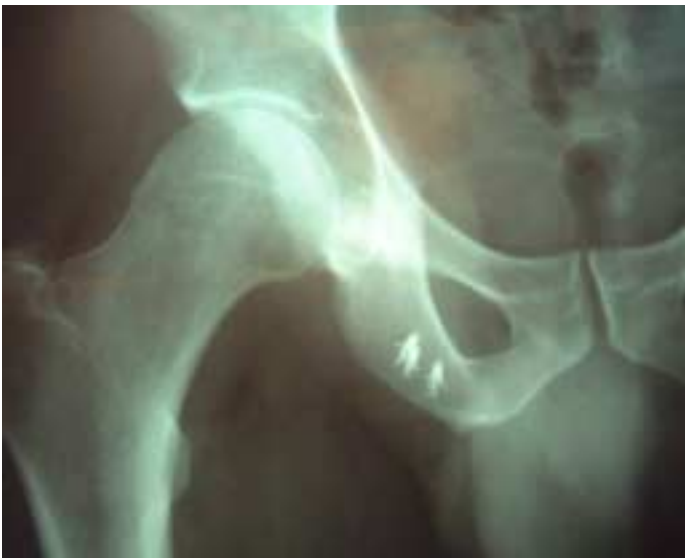

Figure 3. Stay-Tec suture in situ

For 8 weeks after surgery, the knee was flexed at 90⁰ and held in a brace. The sutures were removed at 2 weeks but physiotherapy was not commenced until after the 8-week period. It usually took up to 6 additional weeks before the patient was walking without a limp and had gained full knee extension. In all cases the knee recovered completely from this period of immobilisation.

Strength testing of the hamstring and quadriceps muscles was performed at the centre by one examiner at the time of re-examination for this study, which was an average of 48 months after the surgery. Strength testing of the quadriceps muscles was performed to calculate a quadriceps-to-hamstrings muscle strength ratio.

Muscle strength was measured by finding the weight at which six repetitions (one repetition per second) of a particular motion could be performed with fatigue occurring on the seventh repetition, that is, 6 repetitions maximum (RM). 1 10-minute recovery period was allowed between testing the hamstring and quadriceps muscles. Muscle endurance was measured by finding the number of repetitions of fatigue at 50% of the weight used in achieving the muscles 6 RM in the strength test. The percentage of muscle strength and endurance was calculated by dividing the results for the involved limb by the results of the uninvolved limb.

The patients performed the strength tests on Keiser strengthening equipment (Keiser Sports Health Equipment, Fresno, California). A repeatable protocol was adhered to. Each patient warmed up for 10 minutes on a bike at 250 W and then each patients completed four quadriceps and hamstring muscle stretches for 15 seconds. Each patient was then familiarised with the testing equipment by performing four repetitions without resistance on the Keiser equipment

RESULTS

All patients believed that they had improved with surgery. Hamstring muscle strength testing after surgery ranged from 45% to 88% with an average of 60.2% compared with the uninjured side (Table 2). Hamstring endurance testing ranged fro 26% to 100% with an average of 57.1% compared with the uninjured side. The strength and endurance testing for the quadriceps muscles average 94.57% and 88.28%, respectively, compared with the uninjured side. Physical examination at follow-up revealed all repairs remained intact. The palpable gap and distal mass were not present. Two patients were unavailable for re-examination but when interviewed by phone stated that they were satisfied with the result of the surgery and that the strength had returned to their injured leg. The hip and knee range of motion was similar to the

uninvolved extremity in all patients and the two patients who had suffered sciatic paresthesia before surgery were asymptomatic after surgery.

Seven patients returned to their pre-injury recreational sports, while the eighth patient was planning to return to water skiing next season (Table 1). Two patients (Nos. 5 and 7) who had had attempted to return to sport pre-operatively were not satisfied with their ability to run but were improved after surgery.

Table 2. Strength and Endurance Testing^a

Case	Hamstring Strength	Hamstring Endurance	Quadriceps Strength	Quadriceps Endurance
1	-	-	-	-
2	56	50	100	100
3	88	100	100	100
4	-	-	-	-
5	64	81	91	91
6	47	26	89	72
7	52	44	92	85
8	72	74	82	64
9	43	40	88	81
Average	60.2	57.1	94.6	88.3

^a Percentage of uninjured side

DISCUSSION

Complete rupture of the proximal hamstring in the adult is a rare injury. In the adolescent apophyseal avulsion is well recognised. Wootton et al.³ have reported good results with repair of widely displaced avulsed ischial apophysis. Review of the English literature revealed two case reports of surgical repair of a ruptured proximal hamstring in the adult. Ishikawa et al.² reported two cases treated surgically. The patients in their series were repaired at 5 days and 2 months, respectively (that is, one early and one late repair). In both cases, a satisfactory result was reported. Blasier and Morawa¹ reported a case repaired at 48 hours. At 7 years' follow up the patient was asymptomatic and had resumed recreational sports. Strength testing showed a 9% decrease in hamstring strength.

This is the first report of a series of chronic complete hamstring ruptures treated surgically. In our series the most common cause of this injury (five out of nine patients) was a water skiing fall. In all patients, the mechanism of injury involved a violent eccentric hamstring contraction

with the knee extending and hip flexing.

Clinically the patients had described a tearing sensation during their falls. This had been followed by gross thigh swelling and ecchymosis that resolved over a number of weeks. When first seen at our medical centre, each patient had a posterior mid-thigh mass and a palpable proximal defect, which were accentuated by having the patient perform a hamstring contraction in the prone position. The muscle testing with the patient in the prone position revealed the decrease in power. While being clinically examined before repair, the patients' hamstring contraction was easily overcome as compared with the uninvolved extremity. All patients had had extensive physiotherapy and remained weak. Patients complained of inability to control their leg walking downhill, inability to run and cramping with activity. Two patients had severe radicular symptoms that were after following sciatic nerve neurolysis. In all cases, the decision to perform a surgical repair was based on the patients medical history and physical findings. A preoperative MRI was obtained and confirmed the clinical impression in five cases.

CONCLUSION

All patients had had profound hamstring weakness preoperatively and were satisfied with their improvement in strength after surgery. Seven patients returned to their pre-injury recreation sport, although at a less intense level, and one patient planned to return to his sport (water skiing) during the next season. When tested objectively with strength testing after surgery, there was significant weakness compared to the uninvolved extremity. Hamstring strength averaged 60%, endurance average 57%. Our study showed that reattachment of chronic complete hamstring ruptures can improve patient outcome.

REFERENCES

1. Blasier RB, Morawa LG: Complete rupture of the hamstring origin from a water skiing injury. *Am J Sports Med* 18: 435-437, 1990
2. Ishikawa K, Kai K, Mizuta H: Avulsion of the hamstring muscles from the ischial tuberosity. *Clin Orthop* 232: 153-155, 1988
3. Wootton JR, Cross MJ, Holt KWG: Avulsion of the ischial apophysis. The case for open reduction and internal fixation. *J Bone Joint Surg* 72B: 625-627, 1990